

Suprasellar arachnoid cyst

J.Sales-Llopis

Neurosurgery Department, University General Hospital of Alicante, Foundation for the Promotion of Health and Biomedical Research in the Valencian Region (FISABIO), Alicante, Spain

Suprasellar arachnoid cyst is a type of intracranial arachnoid cyst.

They differ from other arachnoid cysts in several ways, making a separate analysis of these cysts worthwhile.

Epidemiology

In adults suprasellar cysts represent 9% of all the arachnoid cysts while in pediatric population this percentage reaches 15%. ¹⁾

Classification

A suprasellar cyst can be a communicating cyst with a valve at the penetration of the basilar artery (BA) through the prepontine arachnoid membrane or be a noncommunicating cyst ²⁾.

Miyajima et al proposed a classification:

- 1) a noncommunicating intra-arachnoid cyst of the diencephalic Liliequist membrane
- 2) a communicating cyst that is a cystic dilation of the interpeduncular cistern ³⁾.

Pathophysiology

Their presence in utero and their high prevalence in children who have no history of trauma support the assumption that they are congenital ^{4) 5) 6)}, although there is some question as to how early in development the cysts are formed.

These cysts progressively enlarge from an abnormality in the membrane of Liliequist or in the interpeduncular cistern ^{7) 8)}.

Typically, expand from the prepontine space, displacing the floor of the third ventricle upwards, the pituitary stalk and optic chiasm upwards and forwards, and the mammillary bodies upwards and backwards. As the cyst increases in size it fills and occludes the third ventricle, and distorts and blocks the aqueduct, which finally results in hydrocephalus.

A slit-valve mechanism seems to be at least one factor of the genesis of suprasellar prepontine arachnoid cysts ⁹⁾.

In posttraumatic cases one hypothesis is that the inflammatory process due to subdural hematoma may locally result in arachnoiditis, and thus to the creation of a neomembrane, and eventually to cyst

formation ¹⁰⁾.

Histology

Although their true histological nature is rarely known because their membranes are not often analyzed histologically, it is reasonable to think that the majority are arachnoid cysts.

Clinical Features

It can be diagnosed as incidental in asymptomatic patients ¹¹⁾.

There are three reported cases of spontaneous disappearance of a suprasellar arachnoid cyst ¹²⁾.

Obstructive hydrocephalus is the most common cause of initial symptoms and occurs in almost 90% of the patients with suprasellar arachnoid cyst ¹³⁾, and can have varied presentations with [signs](#) and [symptoms](#) of [obstructive hydrocephalus](#) by compressing the third ventricle that require urgent decompression. These patients may present with nonfocal symptoms that can quickly lead to a life-threatening condition if not accurately diagnosed and treated.

Urgent endoscopic third ventriculostomy results in normalization of intracranial pressure, return of normal CSF flow, and relief of symptoms ¹⁴⁾.

Other clinical features

[Visual disturbance](#)

[Endocrine disease](#).

Distortion of the pituitary infundibulum can also result in endocrine dysfunction

Gait [ataxia](#).

Rarely [bobble head doll movement](#) ^{15) 16) 17) 18) 19)}.

Ramesh et al. present three cases with bobble-head doll syndrome associated with a large suprasellar arachnoid cyst and obstructive hydrocephalus ²⁰⁾.

Precocious puberty

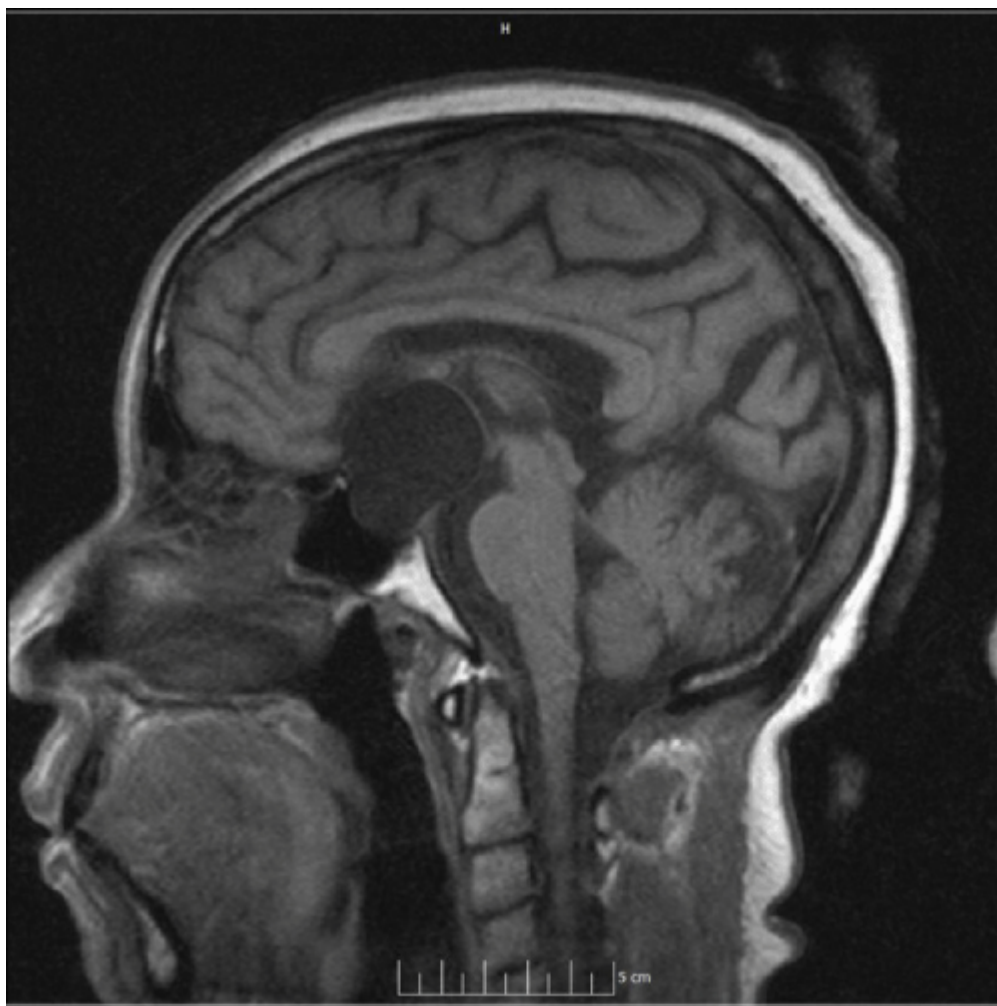
Precocious puberty is rarely the presenting sign. It is characterized by early onset, patent symptoms and frequent association with [growth hormone](#) deficiency. The latter represents a further risk of short stature. Evolution of precocious puberty varied from one case to another, without any relation with the quality of control of the arachnoid cyst and associated hydrocephalus. Half-yearly follow-up of height and bone age allowed for deciding a suppressive treatment of precocious puberty and a substitutive growth hormone therapy when needed ²¹⁾.

Various forms of symptomatic and idiopathic epilepsy and other psychoneurological disorders (disorders of behavior and emotions, obsession-compulsion syndromes, stereotypias, aggression, compulsive ideas and movements, anorexia or hypothalamic obesity) coincident with one or more endocrine disorders such as precocious or delayed puberty, multihormonal pituitary deficiency, panhypopituitarism and secondary hypothyroidism were detected ²²⁾.

Presenting with signs of **normal pressure hydrocephalus**. ²³⁾.

Diagnosis

MRI reveal **cerebrospinal fluid** (CSF) intensity on both **T1**- and **T2**-weighted images ²⁴⁾.



<http://austinpublishinggroup.com/clinical-case-reports/fulltext/images/ajccr-v1-id1021-g001.gif>

As with **arachnoid cysts** elsewhere, they are very thin walled (often imperceptible except on dedicated high resolution T2 imaging) cystic lesions which follow CSF on all imaging modalities. There is no solid component and no enhancement.

These cysts invaginate superiorly into the **third ventricle**, and may even extend into one or both **foramen of Monro**.

Differential diagnosis

Obstructive hydrocephalus at the level of the aqueduct with expansion of the third ventricle floor of the third ventricle should be depressed no cyst wall should be visible or inferred (by CSF flow)

Cystic suprasellar lesions

[Craniopharyngioma](#)

[Rathke's cleft cyst](#)

[Neurocysticercosis](#).

[Hypothalamic hamartomas](#) have been reported to coexist with lesions like Rathke's cleft cyst and arachnoid cysts in the suprasellar or temporo-sylvian regions. ²⁵⁾.

Complications

see [Suprasellar arachnoid cyst postoperative complication](#).

Treatment

Treatment is required when the cyst evolves or the patient is symptomatic, but endocrine disturbances alone are not an indication for surgery.

When hydrocephalus is present, endoscopic fenestration is the primary treatment of choice. The goal of the procedure should be to open the cyst into both the ventricles and the cisterns.

Suprasellar arachnoid cysts can be treated with favorable clinical and radiological results with endoscopic interventions when feasible ^{26) 27) 28)}.

The use of an endoscope in the treatment of suprasellar arachnoid cysts provides an opening of the upper and lower cyst walls, thereby allowing the surgeon to perform a ventriculocystostomy (VC) or a [ventriculocystocisternostomy](#) (VCC). To discover which procedure is appropriate, magnetic resonance (MR)-imaged cerebrospinal fluid (CSF) flow dynamics in two patients were analyzed, one having undergone a VC and the other a VCC using a rigid endoscope. Magnetic resonance imaging studies were performed before and after treatment, with long-term follow-up periods (18 months and 2 years). The two patients were reoperated on during the follow-up period because of slight headache recurrence in one case and MR-imaged CSF flow dynamics modifications in the other. In each case surgery confirmed the CSF flow dynamics modifications appearing on MR imaging. In both cases, long-term MR imaging follow-up studies showed a secondary closing of the upper wall orifice. After VCC, however, the lower communication between the cyst and the cisterns remained functional. The secondary closure of the upper orifice may be explained as follows: when opened, the upper wall becomes unnecessary and tends to return to a normal shape, leading to a secondary closure. The patent sylvian aqueduct aids the phenomenon, as observed after ventriculostomy when the aqueduct is secondarily functional. The simplicity of the VCC performed using endoscopic control, which is the only procedure to allow the opening in the cyst's lower wall to remain patent, leads the authors to advocate this technique in the treatment of suprasellar arachnoid cysts ²⁹⁾.

Results with [ventriculocystocisternostomy](#) are believed superior to those of ventriculocystostomy ³⁰⁾
³¹⁾.

Preoperative cisternography may be useful for selecting the optimal endoscopic treatment method.

If the cyst communicates with the basal cisterns, a ventriculocystostomy could be an effective, safe, and simpler treatment option ³²⁾.

Suprasellar and third ventricular size does respond to the surgical intervention at long-term follow-up ³³⁾.

The endoscopic method is used to treat suprasellar arachnoid cysts (SACs) but it is sometimes difficult to make sufficiently sized fenestrations. Creating a larger fenestration on the cyst wall is preferable to prevent closure of the stoma.

Fuji et al. report a novel endoscopic approach for SAC treatment in which we use bilateral burr holes to achieve a more extensive cyst fenestration. A 7-year-old girl was referred to our hospital because of incidentally detected hydrocephalus by computed tomography scans. Physical examination did not show any signs of intracranial hypertension, but a digital impression of her skull on X-ray implied chronic intracranial hypertension. Magnetic resonance imaging (MRI) revealed enlargement of both lateral ventricles and a cystic mass occupying the third ventricle. They performed cyst wall fenestration using a bilateral approach in which we created two burr holes to introduce a flexible endoscope and a rigid endoscope. The cyst wall was held by forceps with the flexible endoscope, and resection of the cyst wall was achieved by using a pair of scissors with the rigid endoscope. There were no postoperative complications, and MRI performed 1 year after treatment showed disappearance of the superior part of the cyst wall ³⁴⁾.

Postoperative complications

see [Suprasellar arachnoid cyst postoperative complication](#)

Outcome

Intellectual capability after treatment at outcome is not related to age at diagnosis, initial or final cyst size, presence or absence of hydrocephalus, or type of endoscopic treatment ³⁵⁾.

Case series

2016

35 cases of SAC treated between 1996 and 2014. Patient records and imaging studies were reviewed retrospectively to assess symptomatology, radiological findings, treatment, and long-term follow-up.

Fourteen SAC were diagnosed prenatally (39%). They observed 15 (43%) cases presenting hydrocephalus (SAC-1) removing Liliequist membrane downward. Lower forms (SAC-2) with free third ventricle were observed in 11 (31%) cases. Asymmetrical forms (SAC-3) with Sylvian or temporal extension were seen in the 9 (26%) remaining patients. Twenty-three (66%) patients were treated by

ventriculocisternostomy, 3 (8.5%) by shunt surgery, and 3 (8.5%) by craniotomy. Six (17%) patients had no surgery, including 5 cases (14%) that had prenatal diagnosis. Outcomes were initially favorable in 26 cases (87%). Eight (22%) patients had endocrine abnormalities at the end of the follow-up, 3 (8.5%) had developmental delay, and 6 (17%) had minor neuropsychological disturbances.

SAC are heterogeneous entities. SAC-1 may come from an expansion of the diencephalic leaf of the Liliequist membrane. SAC-2 show a dilatation of the interpeduncular cistern and correspond to a defect of the mesencephalic leaf of the Liliequist membrane. SAC-3 correspond to the asymmetrical forms expanding to other subarachnoid spaces. Surgical treatment is not always necessary. The recognition of the different subtypes will allow choosing the best treatment option ³⁶⁾.

2015

Three cases with bobble-head doll syndrome associated with a large suprasellar arachnoid cyst and obstructive hydrocephalus, which were treated with endoscopic cystoventriculocisternostomy and marsupialization of the cyst ³⁷⁾.

2013

4 cases of suprasellar prepontine arachnoid cysts in which a slit valve was identified. The patients presented with hydrocephalus due to enlargement of the cyst. The valve was located in the arachnoid wall of the cyst directly over the basilar artery. Halani et al believe this slit valve was responsible for the net influx of CSF into the cyst and for its enlargement. They also present 1 case of an arachnoid cyst in the middle cranial fossa that had a small circular opening but lacked a slit valve. This cyst did not enlarge but surgery was required because of rupture and the development of a subdural hygroma. One-way slit valves exist and are a possible mechanism of enlargement of suprasellar prepontine arachnoid cysts. The valve was located directly over the basilar artery in each of these cases. Caudad-to-cephalad CSF flow during the cardiac cycle increased the opening of the valve, whereas cephalad-to-caudad CSF flow during the remainder of the cardiac cycle pushed the slit opening against the basilar artery and decreased the size of the opening. Arachnoid cysts that communicate CSF via circular, nonslit valves are probably more likely to remain stable ³⁸⁾.

2011

73 consecutive patients who were treated between June 2002 and September 2009. Twenty-two patients were treated with VC and 51 with VCC. Outcome was assessed by clinical examination and magnetic resonance imaging.

The patients were divided into five groups based on age at presentation: age less than 1 year (n = 6), 1-5 years (n = 36), 6-10 years (n = 15), 11-20 years (n = 11), and 21-53 years (n = 5). The main clinical presentations were macrocrania (100%), motor deficits (50%), and gaze disturbance (33.3%) in the age less than 1 year group; macrocrania (75%), motor deficits (63.9%), and gaze disturbance (27.8%) in the 1-5 years group; macrocrania (46.7%), symptoms of raised intracranial pressure (ICP) (40.0%), endocrine dysfunction (40%), and seizures (33.3%) in the 6-10 years group; symptoms of raised ICP (54.5%), endocrine dysfunction (54.5%), and reduced visual field or acuity (36.4%) in the 11-20 years group; and symptoms of raised ICP (80.0%) and reduced visual field or acuity (40.0%) in

the 21-53 years group. The overall success rate of endoscopic fenestration was 90.4%. A Kaplan-Meier curve for long-term efficacy of the two treatment modalities showed better results for VCC than for VC ($p = 0.008$).

Different age groups with SSCs have different main clinical presentations. VCC appears to be more efficacious than VC ³⁹⁾.

2009

4 suprasellar arachnoid cysts, diminished for different degrees after operation. There were no surgery-related serious complications or deaths. There were not cyst enlarged and stoma obstructed cases ⁴⁰⁾.

2006

Crimmins et al reported on 7 patients treated with ventriculocystostomy (VC) and 13 patients with ventriculocystocisternotomy (VCC). They found VCC had a higher success rate but the difference was not statistically significant ⁴¹⁾.

2004

Wang et al. retrospectively reviewed six cases, in which endoscopic ventriculocystocisternotomy was performed, to identify specific neuroimaging features that aid both the accurate diagnosis of this entity and the postoperative assessment of fenestration patency.

Six consecutive children underwent treatment for suprasellar arachnoid cysts. Consistent radiographic features in all cases were identified. Through a single entry site, endoscopic fenestration was performed at both the apical and basal cyst membranes. Outcome was assessed using clinical examination, quantitative changes in cyst size, and triplanar magnetic resonance (MR) imaging with flow-sensitive (long TR) sequences. In every case, the suprasellar cysts displayed three diagnostic MR imaging features: 1) vertical displacement of the optic chiasm/tracts; 2) upward deflection of the rostral mesencephalon and mammillary bodies; and 3) effacement of the ventral pons. Two patients initially underwent placement of a ventriculoperitoneal shunt before the cysts were recognized, but MR images obtained after shunt placement revealed the cysts. In a mean follow-up period of 26.2 months, all patients improved clinically. Postoperative imaging revealed a mean cyst volume decrease of 52.7% and a return to more normal suprasellar and prepontine anatomy. Flow-sensitive MR imaging confirmed pulsation artifact at all 12 fenestration sites. There was no surgery-related death and no additional cerebrospinal fluid diversion procedure was required.

To aid in the accurate diagnosis of prepontine arachnoid cysts, the authors identified several pathognomonic features on sagittal MR images: vertical deflection of the optic chiasm and mammillary bodies, as well as pontine effacement. Dual endoscopic fenestration into the intraventricular compartment and basal cistern is safe, and it effectively provides symptomatic relief by decreasing the cyst size. Triplanar flow-sensitive MR imaging sequences can confirm fenestration patency without the need for cine-mode MR imaging ⁴²⁾.

2001

Seven patients who had endoscopic treatment; five were children under 15 years old who presented with delayed development and/or enlarged heads. The two adult patients, both of whom had insertion of shunts as children, presented with headache and vomiting due to shunt blockage. All patients improved following endoscopic cyst fenestration. There was no operative morbidity and there have been no relapses to date ⁴³⁾.

1999

Two cases of partial excision of the cyst wall, through a pterional craniotomy, establishing communication with the basal subarachnoid spaces was carried out. The endocrinological symptoms regressed after surgery ⁴⁴⁾.

1989

Five children with ventricular dilatation (4 boys, 1 girl) had features seen on computer tomographic scan that were consistent with suprasellar arachnoid cysts. All children were investigated with a CT ventriculogram and/or CT cisternogram, and no communication with the cyst was demonstrated. Three children were seen in the 1st year of life and the remaining 2 children were between 1 and 5 years of age. Hydrocephalus and developmental delay were the most common presenting features, followed by visual disturbance, squint, or ataxia. Direct surgical decompression was performed in all 5 patients to avoid long-term placement of a ventriculoperitoneal shunt. A temporary shunt was placed in 2 children because of high intracranial pressure. Direct partial excision of the cyst wall to allow long-term drainage into the basal cisterns or ventricular system was successful in all children. The presence of subdural collections postoperatively required temporary shunting in 2 children. After follow-up for between 10 and 22 months no clinical endocrinological sequelae have been detected, but 2 children have raised serum prolactin levels. Three children are developmentally delayed; one of these has regained some skills since surgery ⁴⁵⁾.

Case reports

2015

A [premature neonate](#) who developed a large, acquired arachnoid cyst as a consequence of intraventricular haemorrhage. The child was managed with endoscopic fenestration and made an excellent recovery ⁴⁶⁾.

2014

Rao et al. report a Giant suprasellar arachnoid cyst presenting with precocious puberty ⁴⁷⁾.

2005

A 67-year-old man first noticed loss of pubic and axillary hair in 1992 and then a visual field defect in 2001. He experienced loss of consciousness attributed to hyponatremia in April 2002. Magnetic resonance imaging showed a giant intrasellar cystic mass, 40 mm in diameter, that had compressed the optic chiasm. The patient complained of chronic headache, and neurological examination revealed bitemporal hemianopsia. Preoperative endocrinological examination indicated adrenal insufficiency, and hypothyroidism due to hypothalamic dysfunction. The patient underwent endonasal transsphenoidal surgery. The cyst membrane was opened and serous fluid was drained. Histological examination identified the excised cyst membrane as arachnoid membrane. The patient's headaches resolved postoperatively, but the bitemporal hemianopsia and endocrinological function were unchanged. This arachnoid cyst associated with hypothalamic dysfunction might have been caused by an inflammatory episode in the suprasellar region ⁴⁸⁾.

1995

Santamarta et al. report one case of a suprasellar arachnoid cyst in which a slit-valve mechanism observed by means of cine-mode MRI preoperatively and confirmed during the endoscopic intervention ⁴⁹⁾.

Kaisho et al followed a case of suprasellar arachnoid cyst for 12 years. The patient was a sixteen-year-old girl without particular problems in her general condition. She showed optic atrophy in both eyes and optic nerve hypoplasia with an inferotemporal quadrantanopsia in the left eye. A suprasellar arachnoid cyst communicating with the tubarachnoid space was found to extend into the sella turcica as an empty sella. A cyst wall was resected and a cyst-peritoneal shunt performed. After 12 years from the operation, sensitivity was slightly depressed in the visual field where it had already been disturbed. Although there are few reports in the literature on involvement of the optic nerves and chiasma by suprasellar arachnoid cysts, papilledema and optic atrophy are often found in children, and infero-temporal quadrantanopsia or homonymous hemianopsia have been reported. Visual field defects were most likely caused by compression of the optic nerve by cyst or prolonged papilledema. They also suspect that some kind of disturbance to the optic nerve occurred during extension of the arachnoid cyst as an empty sella, or during formation of arachnoid cyst in the fetus stage ⁵⁰⁾.

1993

Rosso et al report a case of periodic sweating with multifocal dystonia is reported in a 60-year-old woman. At the age of 48 years, she presented with involuntary twisting of the lower face on the right. Six months later she noticed similar movements in the head and right arm. Four years later she began having attacks of generalized sweating over the whole face, anterior region of the trunk and both arms. The attacks occurred hourly each and every day. They lasted for about 10 min and were followed by voluntary urinary voiding. The biochemical and laboratory investigations showed no abnormalities except for the luteinizing hormone and follicle-stimulating hormone values that were below normal. The computerized tomography and magnetic resonance imaging scans revealed a suprasellar cyst ⁵¹⁾.

1991

A 53-year-old man was admitted because of decreased visual acuity. Magnetic resonance imaging showed a large intrasellar cyst extending into the suprasellar cistern, with compression of optic nerves. The intensity of the cyst was identical to that of the surrounding subarachnoid space on both T1-, T2-, and proton density-weighted images. Transsphenoidal surgery was performed, but subsequent refilling of the cyst required additional transcranial surgery. Analysis of the cerebrospinal fluid-like cystic fluid revealed high levels of protein and pituitary hormones. Histological study revealed that the cyst wall was composed of connective tissue and arachnoid cells, which were ultrastructurally characterized by a number of desmosomes ⁵²⁾.

1988

A 2-year-old infant who presented with paroxysm and short changes characterized by acute drowsiness, cold sweats, ocular reversion, facial cyanosis, and bradycardia. Between these attacks, the condition was normal, suggesting diencephalic seizures. Over 2 months five fits were observed by the parents when some to-and-fro bobbing of the head onto the trunk appeared during drowsiness. One electroencephalogram was normal without a slow background or spikes discharges. As the skull radiographs showed erosion of the jugum and chronic intracranial hypertension features, a CT scan was performed and showed hydrocephalus associated with a congenital suprasellar cyst. The cyst was opened into basal cisterns with cystoperitoneal shunt. The histological examination revealed that it was an arachnoid cyst. Six months later, the infant was free of diencephalic seizures and head bobbing. Thus, we can assert that there was a direct relationship between this cyst and the diencephalic seizures. From this case, the authors make a review of the clinical features of diencephalic epilepsy, and their different causes and show that both diencephalic epilepsy and suprasellar arachnoid cysts are not common ⁵³⁾.

De novo suprasellar arachnoid cyst

2015

A case of a 2-year-old boy who presented with instability and episodes of ocular deviation. A computed tomography scan (CT scan) and magnetic resonance imaging (MRI) of the brain revealed a suprasellar cyst and obstructive hydrocephalus. At birth a transfontanellar ultrasound was normal. The cyst underwent endoscopic fenestration with complete remission of symptoms. In the review of the literature, Gelabert-González et al. found only 6 previous cases of an intracranial arachnoid cyst whose origin was not clearly congenital or traumatic, and Gelabert-González et al. is the second case of a suprasellar arachnoid cyst to arise de novo ⁵⁴⁾.

2012

A 4-year-old child who was incidentally found to have a suprasellar arachnoid cyst (SAC) after initial CT imaging at 6 weeks of age but who demonstrated no anomalies. This is only the sixth case of intracranial de novo ACs documented in the English literature and only the second case of SAC to

arise de novo.

With the use of fast MRI scans instead of CT scans and the continued neuroimaging of premature infants, we can take a better look at the anatomy and better determine the timing of development of the SAC ⁵⁵⁾

References

¹⁾

Hinojosa J, Esparza J, Muñoz MJ, Valencia J. [Endoscopic treatment of suprasellar arachnoid cysts]. Neurocirugia (Astur). 2001 Dec;12(6):482-8; discussion 489. Review. Spanish. PubMed PMID: 11787396.

²⁾

Pierre-Kahn A, Capelle L, Brauner R, Sainte-Rose C, Renier D, Rappaport R, Hirsch JF: Presentation and management of suprasellar arachnoid cysts. Review of 20 cases. J Neurosurg 1990, 73:355-9.

³⁾ , ⁸⁾

Miyajima M, Arai H, Okuda O, Hishii M, Nakanishi H, Sato K: Possible origin of suprasellar arachnoid cysts: neuroimaging and neurosurgical observations in nine cases. J Neurosurg 2000, 93:62-7.

⁴⁾

Golash A, Mitchell G, Mallucci C, May P, Pilling D: Prenatal diagnosis of suprasellar arachnoid cyst and postnatal endoscopic treatment. Childs Nerv Syst 2001, 17:739-42.

⁵⁾

Pierre-Kahn A, Hanlo P, Sonigo P, Parisot D, McConnell RS: The contribution of prenatal diagnosis to the understanding of malformative intracranial cysts: state of the art. Childs Nerv Syst 2000, 16:619-26.

⁶⁾

Raffel C, McComb JG: To shunt or to fenestrate: which is the best surgical treatment for arachnoid cysts in pediatric patients? Neurosurgery 1988, 23:338-42.

⁷⁾

Binitie O, Williams B, Case CP: A suprasellar subarachnoid pouch; aetiological considerations. J Neurol Neurosurg Psychiatry 1984, 47:1066-74.

⁹⁾

Schroeder HW, Gaab MR. Endoscopic observation of a slit-valve mechanism in a suprasellar prepontine arachnoid cyst: case report. Neurosurgery. 1997 Jan;40(1):198-200. PubMed PMID: 8971844.

¹⁰⁾

Sonnet MH, Joud A, Marchal JC, Klein O. Suprasellar arachnoid cyst after subdural haemorrhage in an infant. A case based update. Neurochirurgie. 2014 Feb-Apr;60(1-2):55-8. doi: 10.1016/j.neuchi.2014.01.003. Epub 2014 Mar 18. PubMed PMID: 24656261.

¹¹⁾

Monsalve G, Luque JC. Giant suprasellar arachnoid cyst. A case with severe brain stem compression: an incidental finding in a head trauma. Pediatr Neurosurg. 2007;43(2):174-6. PubMed PMID: 17337937.

¹²⁾

Moon KS, Lee JK, Kim JH, Kim SH. Spontaneous disappearance of a suprasellar arachnoid cyst: case report and review of the literature. Childs Nerv Syst. 2007 Jan;23(1):99-104. Epub 2006 Aug 30. PubMed PMID: 16944178.

¹³⁾

Al-Holou WN, Terman S, Kilburg C, Garton HJ, Muraszko KM, Maher CO. Prevalence and natural history of arachnoid cysts in adults. J Neurosurg. 2013 Feb;118(2):222-31. doi: 10.3171/2012.10.JNS12548. Epub 2012 Nov 9. PubMed PMID: 23140149.

¹⁴⁾

Mattox A, Choi JD, Leith-Gray L, Grant GA, Adamson DC. Guidelines for the management of

obstructive hydrocephalus from suprasellar-prepontine arachnoid cysts using endoscopic third ventriculocystocisternostomy. *Surg Innov.* 2010 Sep;17(3):206-16. doi: 10.1177/1553350610377212. Epub 2010 Aug 5. Review. PubMed PMID: 20688773.

15)

Wiese JA, Gentry LR, Menezes AH. Bobble-head doll syndrome: review of the pathophysiology and CSF dynamics. *Pediatr Neurol.* 1985 Nov-Dec;1(6):361-6. Review. PubMed PMID: 3916908.

16)

Fioravanti A, Godano U, Consales A, Mascari C, Calbucci F. Bobble-head doll syndrome due to a suprasellar arachnoid cyst: endoscopic treatment in two cases. *Childs Nerv Syst.* 2004 Oct;20(10):770-3. PubMed PMID: 15057560.

17)

Van Beijnum J, Hanlo PW, Han KS, Ludo Van der Pol W, Verdaasdonk RM, Van Nieuwenhuizen O. Navigated laser-assisted endoscopic fenestration of a suprasellar arachnoid cyst in a 2-year-old child with bobble-head doll syndrome. Case report. *J Neurosurg.* 2006 May;104(5 Suppl):348-51. PubMed PMID: 16848093.

18)

Alexiou GA, Sfakianos G, Prodromou N. Giant suprasellar arachnoid cyst with head bobbing. *Mov Disord.* 2013 Aug;28(9):1216. doi: 10.1002/mds.25511. Epub 2013 Aug 2. PubMed PMID: 23913743.

19)

Hagebeuk EE, Kloet A, Grotenhuis JA, Peeters EA. Bobble-head doll syndrome successfully treated with an endoscopic ventriculocystocisternostomy. Case report and review of the literature. *J Neurosurg.* 2005 Sep;103(3 Suppl):253-9. PubMed PMID: 16238079.

20) 37)

Ramesh S, Raju S. Suprasellar arachnoid cyst presenting with bobble-head doll syndrome: Report of three cases. *J Pediatr Neurosci.* 2015 Jan-Mar;10(1):18-21. doi: 10.4103/1817-1745.154321. PubMed PMID: 25878736; PubMed Central PMCID:PMC4395937.

21)

Brauner R, Pierre-Kahn A, Nemedi-Sandor E, Rappaport R, Hirsch JF. [Precocious puberty caused by a suprasellar arachnoid cyst. Analysis of 6 cases]. *Arch Fr Pediatr.* 1987 Aug-Sep;44(7):489-93. French. PubMed PMID: 3426371.

22)

Starzyk J, Kwiatkowski S, Kaciński M, Krocza S, Wójcik M. [Structural CNS abnormalities responsible for coincidental occurrence of endocrine disorders, epilepsy and psychoneurologic disorders in children and adolescents]. *Przegl Lek.* 2010;67(11):1120-6. Polish. PubMed PMID: 21442961.

23)

De Bonis P, Novegno F, Tamburrini G, Anile C, Pompucci A, Mangiola A. Teaching NeuroImage: Prepontine-suprasellar arachnoid cyst presenting with signs of normal pressure hydrocephalus. *Neurology.* 2008 Feb 5;70(6):e26. doi: 10.1212/01.wnl.0000296823.01603.44. PubMed PMID: 18250284.

24)

Oyama K, Fukuhara N, Taguchi M, Takeshita A, Takeuchi Y, Yamada S. Transsphenoidal cyst cisternostomy with a keyhole dural opening for sellar arachnoid cysts: technical note. *Neurosurg Rev.* 2014 Apr;37(2):261-7; discussion 267. doi: 10.1007/s10143-013-0496-4. Epub 2013 Sep 3. PubMed PMID: 23999887.

25)

Manjila S, Vogel TW, Chen Y, Rodgers MS, Cohen AR. Hypothalamic hamartoma simulating a suprasellar arachnoid cyst: resolution of precocious puberty following microsurgical lesion resection. *J Neurosurg Pediatr.* 2014 Jul;14(1):101-7. doi: 10.3171/2014.4.PEDS13371. Epub 2014 May 16. PubMed PMID: 24835046.

26)

Pei A, Zhang YZ, Zong XY, Wang XS, Song M. [Endoscopic treatment of suprasellar arachnoid cysts]. *Zhonghua Yi Xue Za Zhi.* 2007 Jan 30;87(5):311-4. Chinese. PubMed PMID: 17456358.

27)

Erşahin Y, Kesikçi H, Rüksen M, Aydın C, Mutluer S. Endoscopic treatment of suprasellar arachnoid cysts. *Childs Nerv Syst.* 2008 Sep;24(9):1013-20. doi: 10.1007/s00381-008-0615-7. Epub 2008 Apr 4. PubMed PMID: 18389259.

28)

Dagain A, Lepeintre JF, Scarone P, Costache C, Dupuy M, Gaillard S. Endoscopic removal of a suprasellar arachnoid cyst: an anatomical study with special reference to skull base. *Surg Radiol Anat.* 2010 Apr;32(4):389-92. doi: 10.1007/s00276-009-0579-7. Epub 2009 Oct 24. PubMed PMID: 19855917.

29)

Decq P, Brugieres P, Le Guerin C, Djindjian M, Keravel Y, Nguyen JP. Percutaneous endoscopic treatment of suprasellar arachnoid cysts: ventriculocystostomy or ventriculocystocisternostomy? Technical note. *J Neurosurg.* 1996 Apr;84(4):696-701. PubMed PMID: 8613867.

30)

El-Ghandour NM. Endoscopic treatment of suprasellar arachnoid cysts in children. *J Neurosurg Pediatr.* 2011 Jul;8(1):6-14. doi: 10.3171/2011.4.PEDS1184. PubMed PMID: 21721882.

31)

Ozek MM, Urgun K. Neuroendoscopic management of suprasellar arachnoid cysts. *World Neurosurg.* 2013 Feb;79(2 Suppl):S19.e13-8. doi: 10.1016/j.wneu.2012.02.011. Epub 2012 Feb 10. Review. PubMed PMID: 22381821.

32)

Ogiwara H, Morota N, Joko M, Hirota K. Endoscopic fenestrations for suprasellar arachnoid cysts. *J Neurosurg Pediatr.* 2011 Nov;8(5):484-8. doi: 10.3171/2011.8.PEDS11226. PubMed PMID: 22044374.

33)

Rizk E, Chern JJ, Tagayun C, Tubbs RS, Hankinson T, Rozzelle C, Oakes WJ, Blount JP, Wellons JC. Institutional experience of endoscopic suprasellar arachnoid cyst fenestration. *Childs Nerv Syst.* 2013 Aug;29(8):1345-7. doi: 10.1007/s00381-013-2032-9. Epub 2013 Jan 24. PubMed PMID: 23345020.

34)

Fujio S, Bunyamin J, Hirano H, Oyoshi T, Sadamura Y, Bohara M, Arita K. A Novel Bilateral Approach for Suprasellar Arachnoid Cysts: A Case Report. *Pediatr Neurosurg.* 2015 Oct 29. [Epub ahead of print] PubMed PMID: 26509420.

35) 41)

Crimmins DW, Pierre-Kahn A, Sainte-Rose C, Zerah M. Treatment of suprasellar cysts and patient outcome. *J Neurosurg.* 2006 Aug;105(2 Suppl):107-14. PubMed PMID: 16922071.

36)

André A, Zerah M, Roujeau T, Brunelle F, Blauwblomme T, Puget S, Bourgeois M, Sainte-Rose C, Ville Y, Di Rocco F. Suprasellar Arachnoid Cysts: Toward a New Simple Classification Based on Prognosis and Treatment Modality. *Neurosurgery.* 2016 Mar;78(3):370-80. doi: 10.1227/NEU.0000000000001049. PubMed PMID: 26445374.

38)

Halani SH, Safain MG, Heilman CB. Arachnoid cyst slit valves: the mechanism for arachnoid cyst enlargement. *J Neurosurg Pediatr.* 2013 Jul;12(1):62-6. doi: 10.3171/2013.4.PEDS12609. Epub 2013 May 10. PubMed PMID: 23662935.

39)

Gui SB, Wang XS, Zong XY, Zhang YZ, Li CZ. Suprasellar cysts: clinical presentation, surgical indications, and optimal surgical treatment. *BMC Neurol.* 2011 May 18;11:52. doi: 10.1186/1471-2377-11-52. PubMed PMID: 21586175; PubMed Central PMCID: PMC3119168.

40)

Hu ZQ, Zhu GT, Huang H, Dai B, Xiao ZY, Guan F, Zhang Y. [Endoscopic therapy for obstructive hydrocephalus caused by cysts in the pathway of CSF circulation]. *Zhonghua Yi Xue Za Zhi.* 2009 May 5;89(17):1179-84. Chinese. PubMed PMID: 19595082.

42)

Wang JC, Heier L, Souweidane MM. Advances in the endoscopic management of suprasellar arachnoid cysts in children. *J Neurosurg.* 2004 May;100(5 Suppl Pediatrics):418-26. Erratum in: *J Neurosurg.*

2004 Aug;101(1 Suppl):123. PubMed PMID: 15287448.

43)

Fitzpatrick MO, Barlow P. Endoscopic treatment of prepontine arachnoid cysts. *Br J Neurosurg*. 2001 Jun;15(3):234-8. PubMed PMID: 11478058.

44)

Gupta SK, Gupta VK, Khosla VK, Dash RJ, Bhansali A, Kak VK, Vasishta RK. Suprasellar arachnoid cyst presenting with precocious puberty : report of two cases. *Neurol India*. 1999 Jun;47(2):148-51. PubMed PMID: 10402344.

45)

Jones RF, Warnock TH, Nayanar V, Gupta JM. Suprasellar arachnoid cysts: management by cyst wall resection. *Neurosurgery*. 1989 Oct;25(4):554-61. PubMed PMID: 2797393.

46)

Palin M, Anderson I, O'Reilly G, Goodden JR. A suprasellar arachnoid cyst resulting from an intraventricular haemorrhage and showing complete resolution following endoscopic fenestration. *BMJ Case Rep*. 2015 Apr 29;2015. pii: bcr2015209290. doi: 10.1136/bcr-2015-209290. PubMed PMID: 25926587.

47)

Rao K, Levy ML, Crawford JR. Giant suprasellar arachnoid cyst presenting with precocious puberty. *BMJ Case Rep*. 2014 Aug 19;2014. pii: bcr2014205750. doi: 10.1136/bcr-2014-205750. PubMed PMID: 25139925.

48)

Yasuda K, Saitoh Y, Okita K, Morris S, Moriwaki M, Miyagawa J, Yoshimine T. Giant intrasellar arachnoid cyst manifesting as adrenal insufficiency due to hypothalamic dysfunction-case report-. *Neurol Med Chir (Tokyo)*. 2005 Mar;45(3):164-7. PubMed PMID: 15782010.

49)

Santamarta D, Aguas J, Ferrer E. The natural history of arachnoid cysts: endoscopic and cine-mode MRI evidence of a slit-valve mechanism. *Minim Invasive Neurosurg*. 1995 Dec;38(4):133-7. Review. PubMed PMID: 8750654.

50)

Kaisho Y, Miyazaki S, Shimo-oku M, Hayashi T, Tani E. [A case of suprasellar arachnoid cyst followed up for a long time]. *Nihon Ganka Gakkai Zasshi*. 1995 Jan;99(1):109-14. Review. Japanese. PubMed PMID: 7887322.

51)

Rosso AL, Mattos JP, Novis SA. A case of periodic sweating associated with a subarachnoid cyst and multifocal dystonia. *Clin Auton Res*. 1993 Oct;3(5):299-301. PubMed PMID: 8124061.

52)

Hasegawa M, Yamashima T, Yamashita J, Kuroda E. Symptomatic intrasellar arachnoid cyst: case report. *Surg Neurol*. 1991 May;35(5):355-9. PubMed PMID: 2028382.

53)

Giroud M, Sautreaux JL, Thierry A, Dumas R. Diencephalic epilepsy with congenital suprasellar arachnoid cyst in an infant. *Childs Nerv Syst*. 1988 Aug;4(4):252-4. PubMed PMID: 3167881.

54)

Gelabert-González M, Pita-Buezas L, Santín-Amo JM, Román-Pena P, Serramito-García R, García-Allut A. [«De novo» development of a suprasellar arachnoid cyst]. *Neurocirugia (Astur)*. 2015 Mar-Apr;26(2):100-4. doi: 10.1016/j.neucir.2014.09.007. Epub 2015 Feb 2. Spanish. PubMed PMID: 25656308.

55)

Invergo D, Tomita T. De novo suprasellar arachnoid cyst: case report and review of the literature. *Pediatr Neurosurg*. 2012;48(3):199-203. doi: 10.1159/000345636. Epub 2013 Feb 13. Review. PubMed PMID: 23407142.

From:

<https://neurocirugiacontemporanea.es/wiki/> - **Neurocirugía Contemporánea ISSN 1988-2661**

Permanent link:

https://neurocirugiacontemporanea.es/wiki/doku.php?id=suprasellar_arachnoid_cyst

Last update: **2025/05/04 00:04**

